

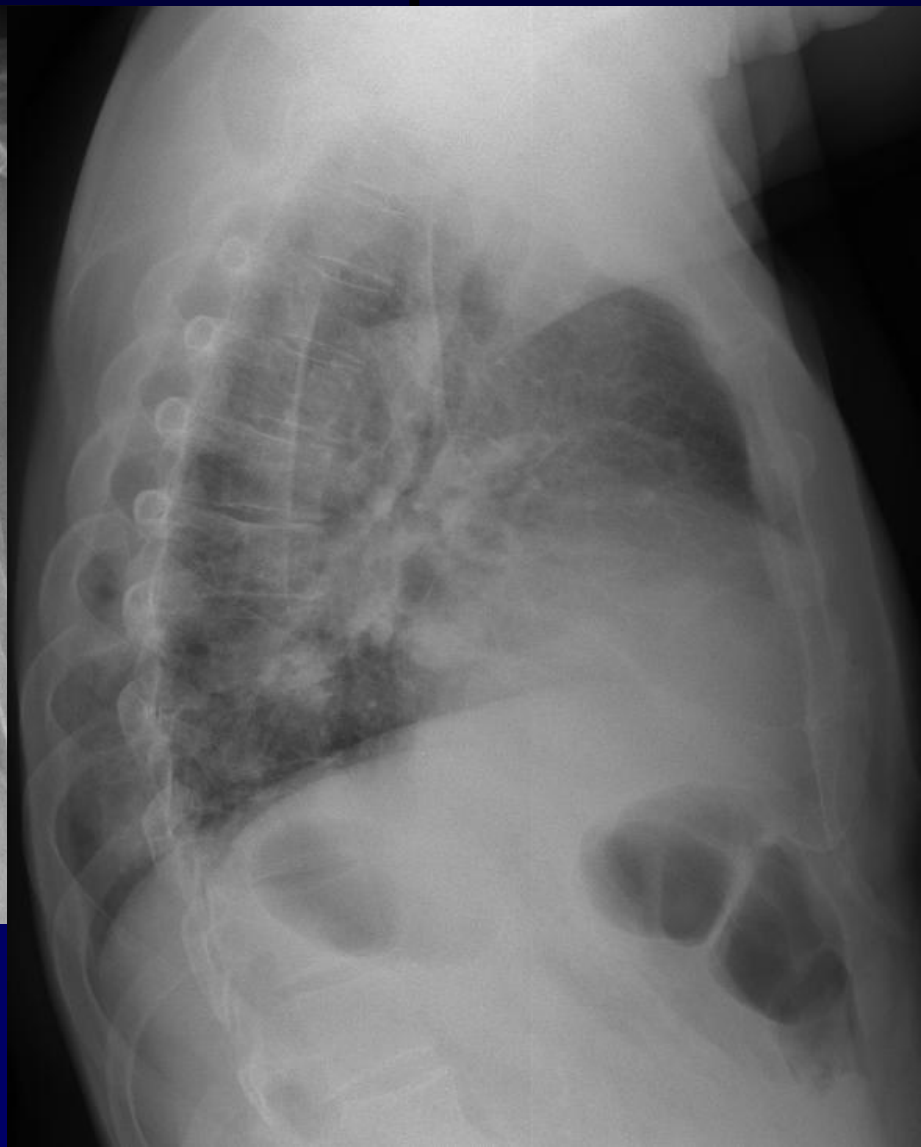
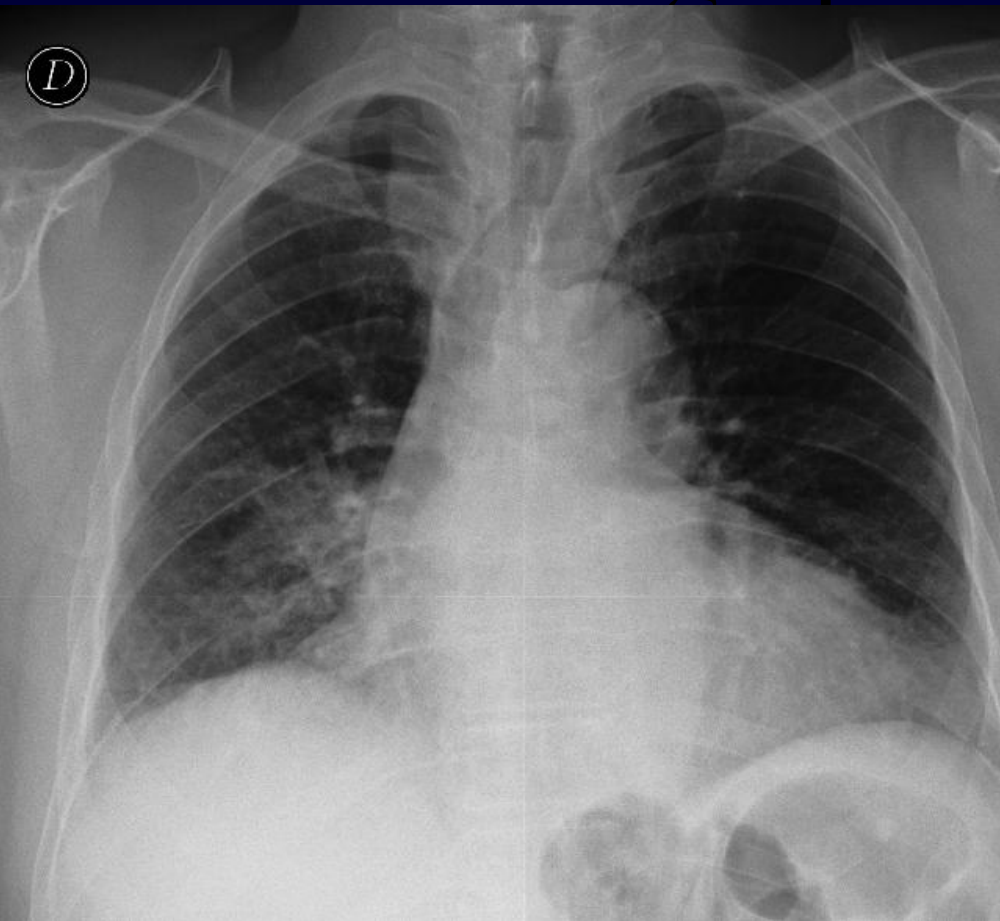


**A Khalil – MF Carette**

**Homme, 72 ans hospitalisé pour l'exploration d'une masse tumorale**

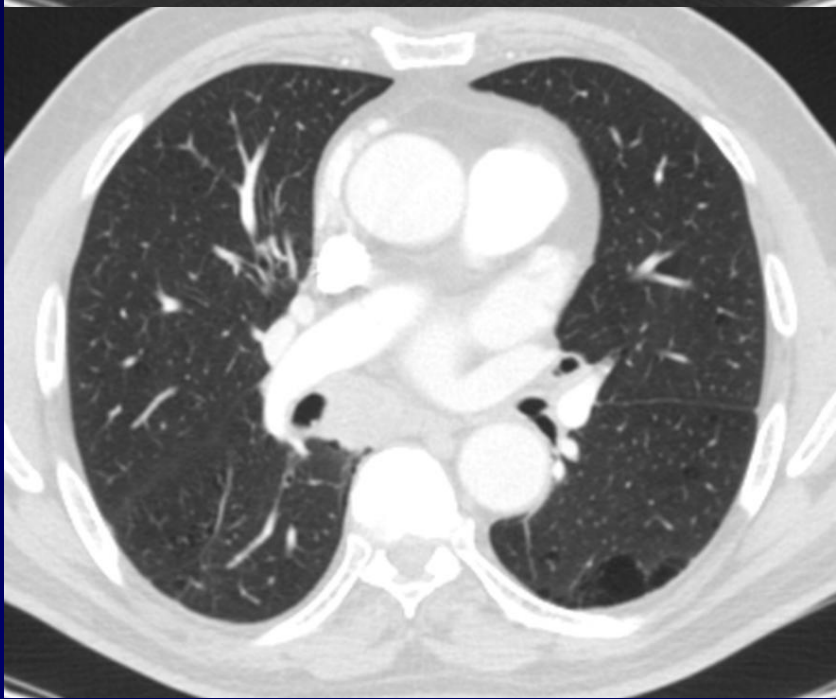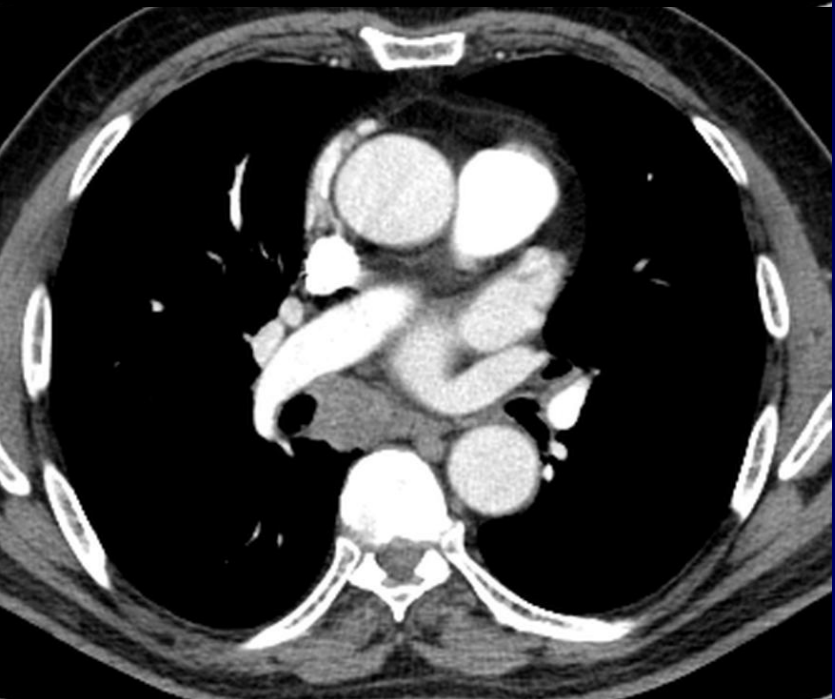
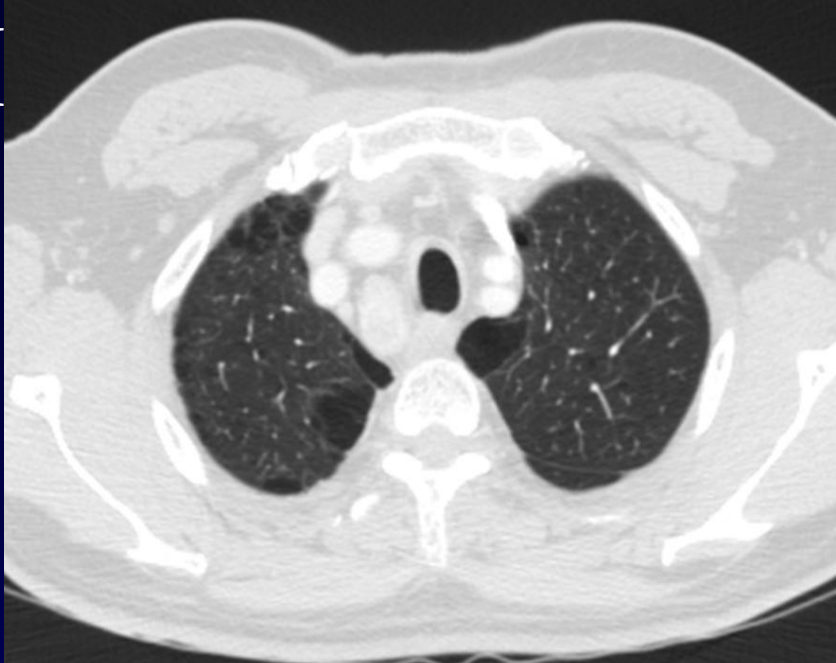
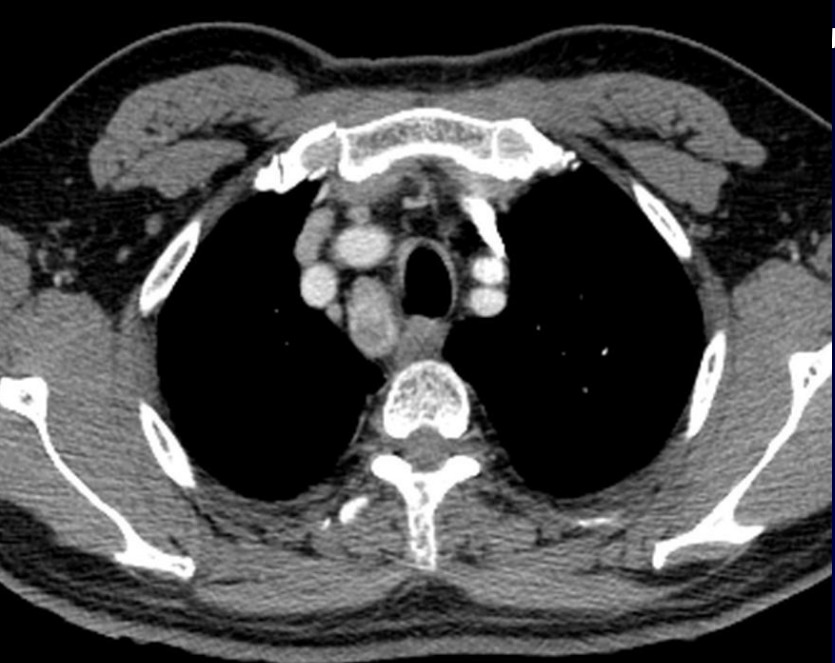


# Radiographie thoracique



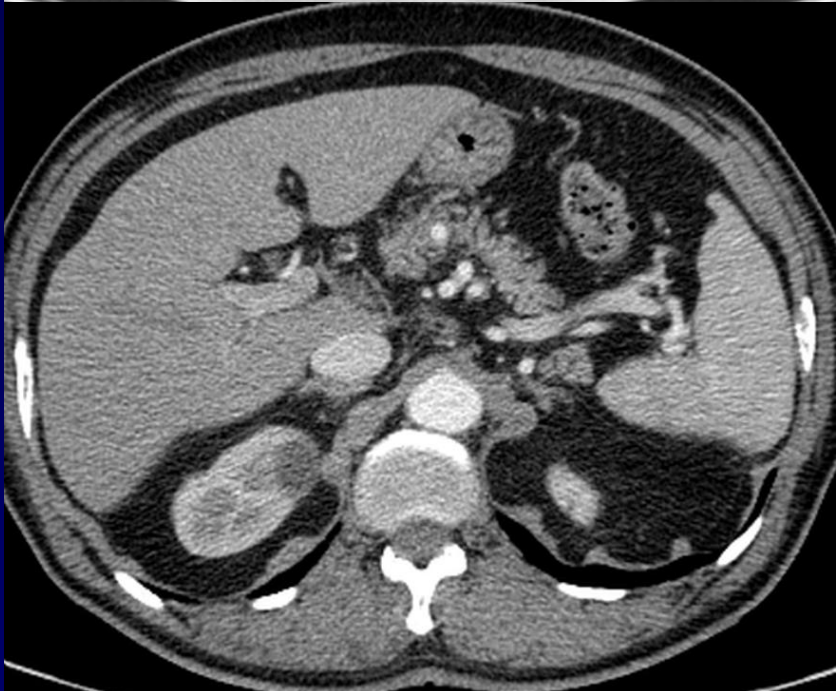
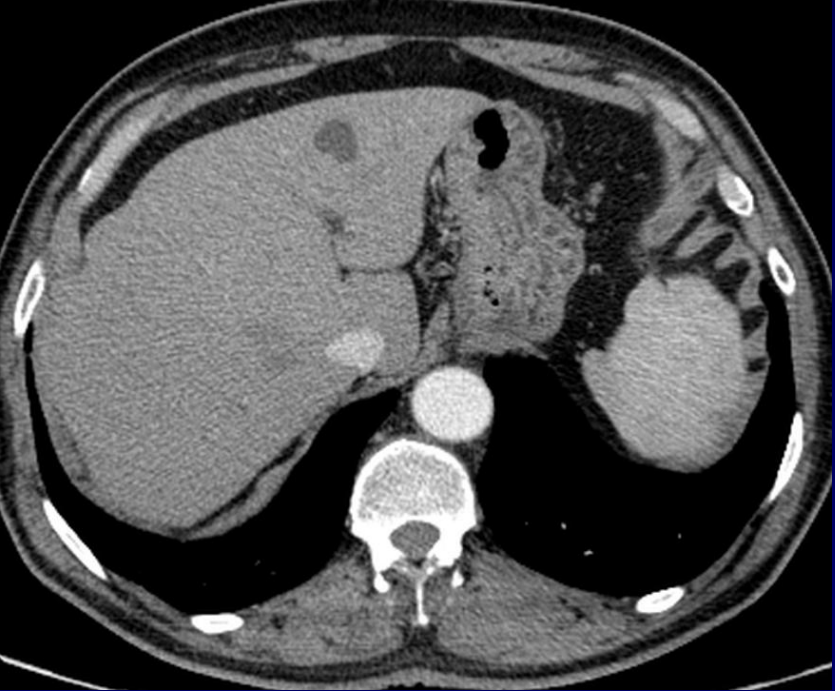
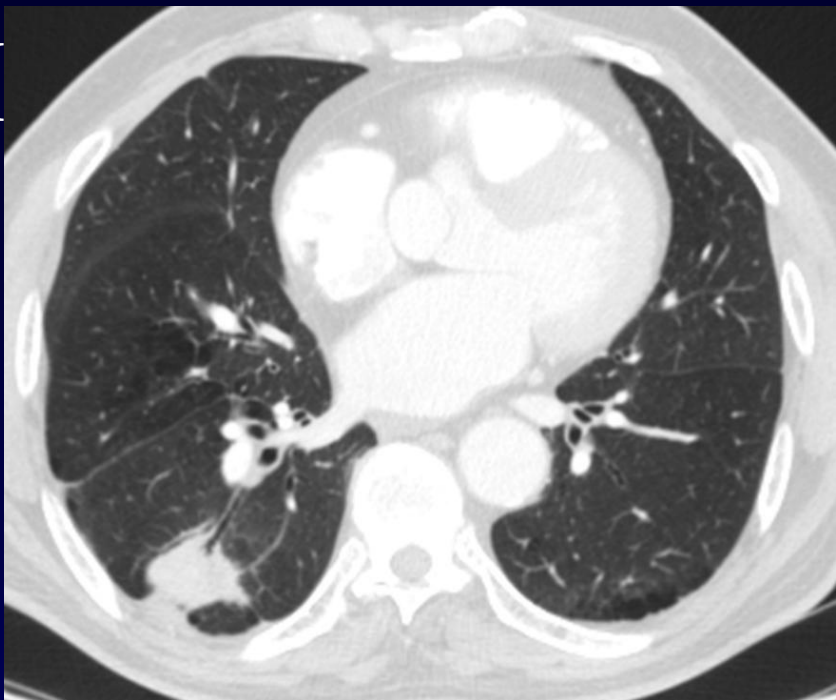
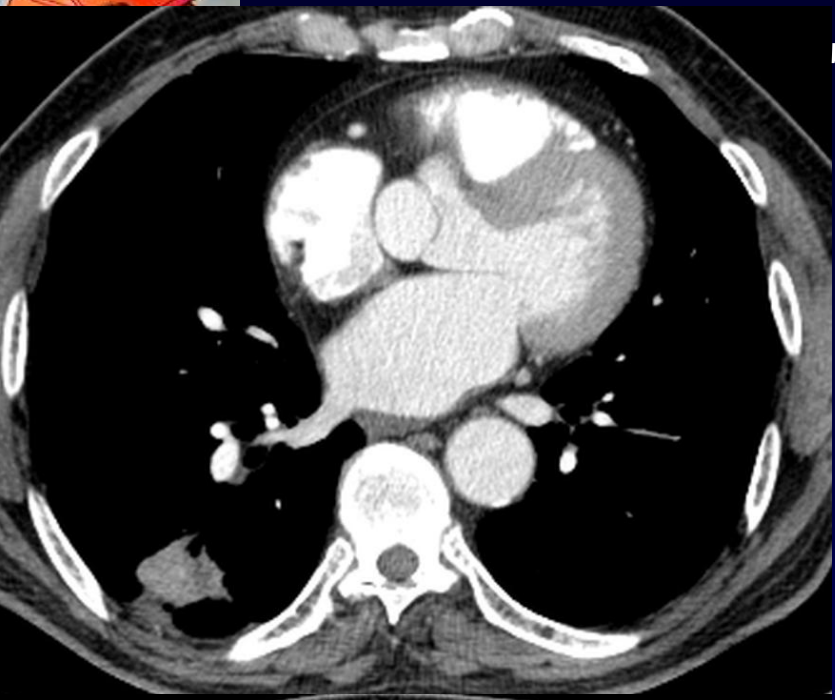


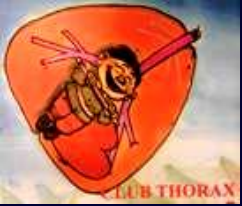TDM





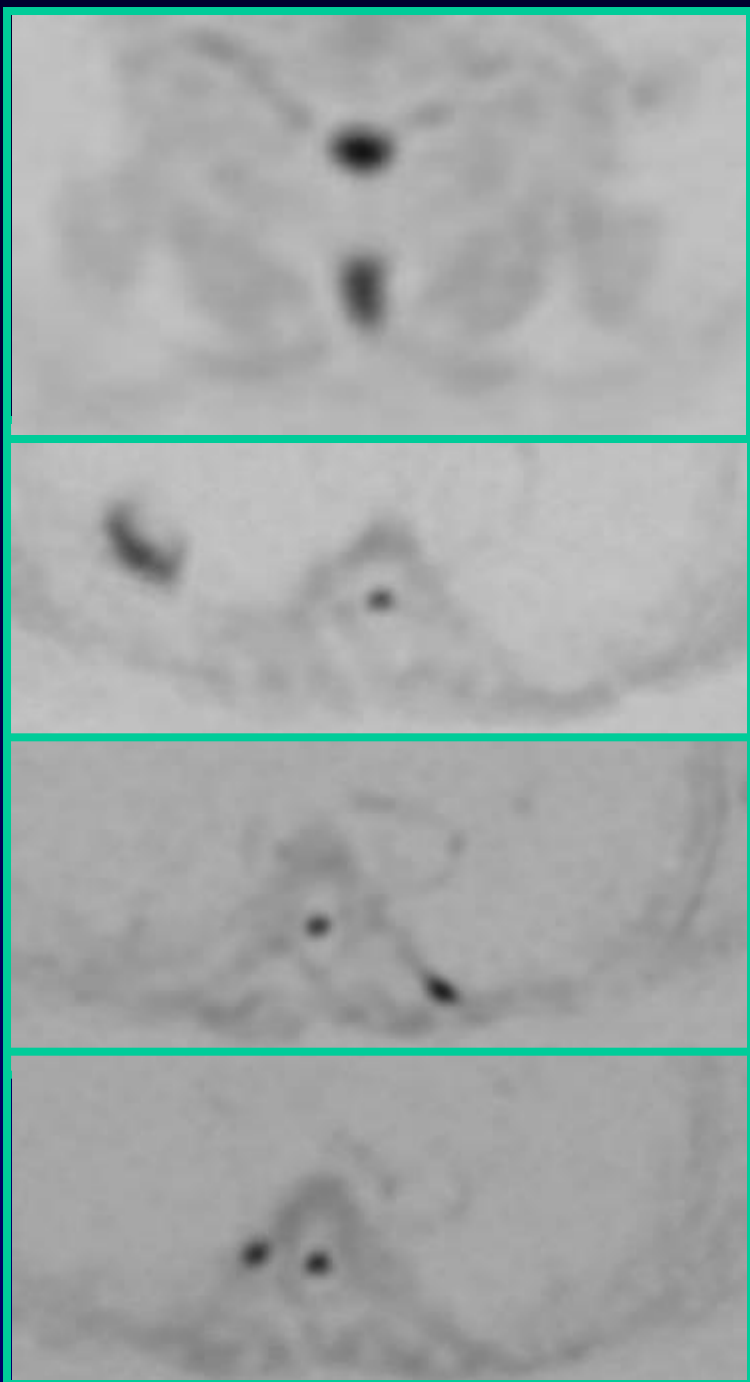
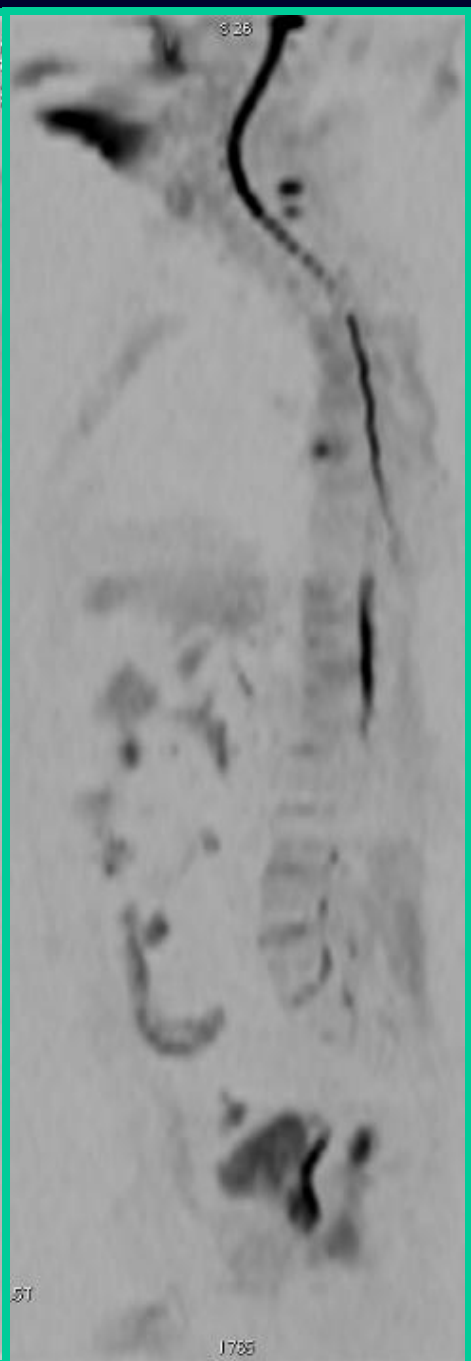
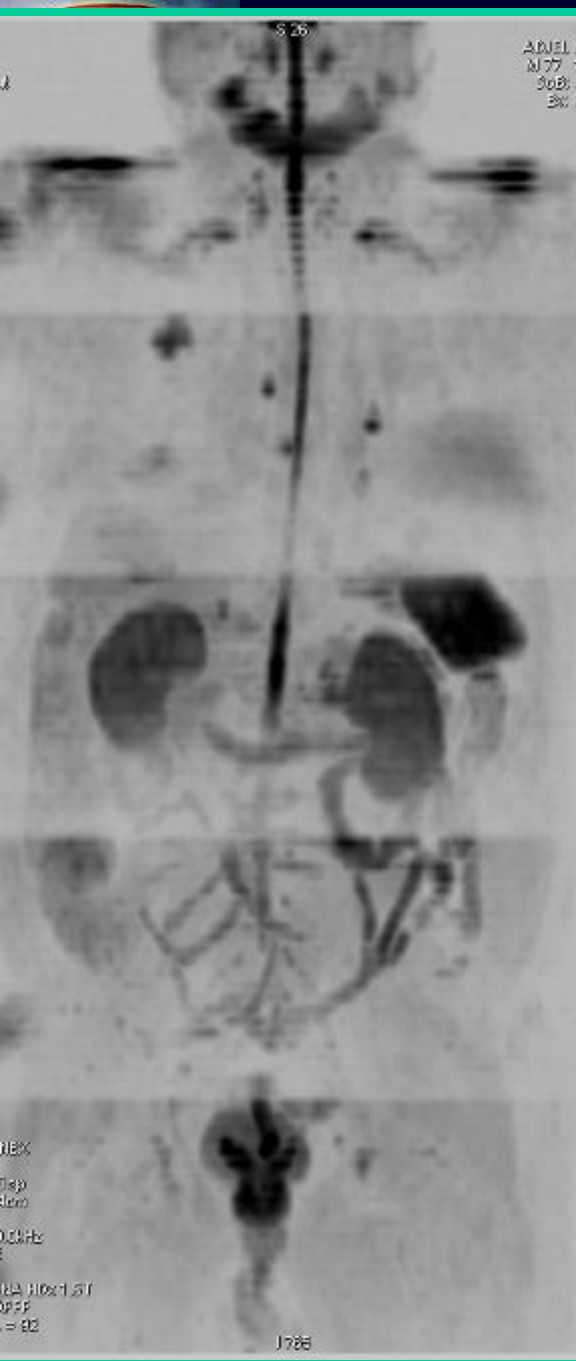TDM



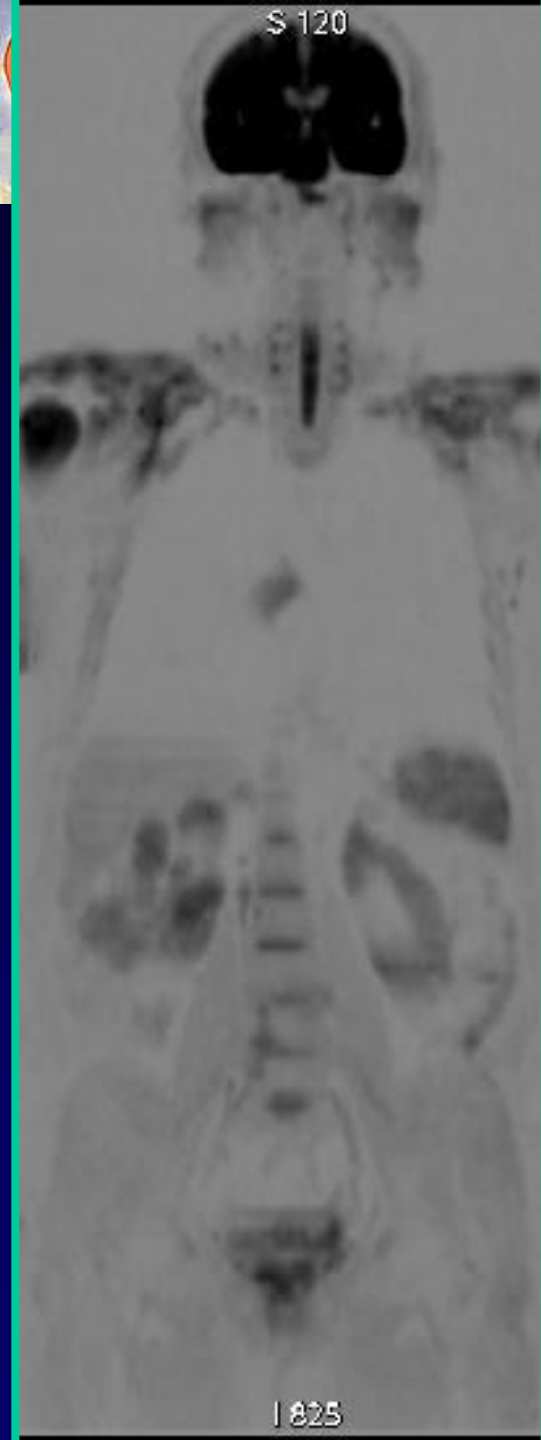

# La classification TNM

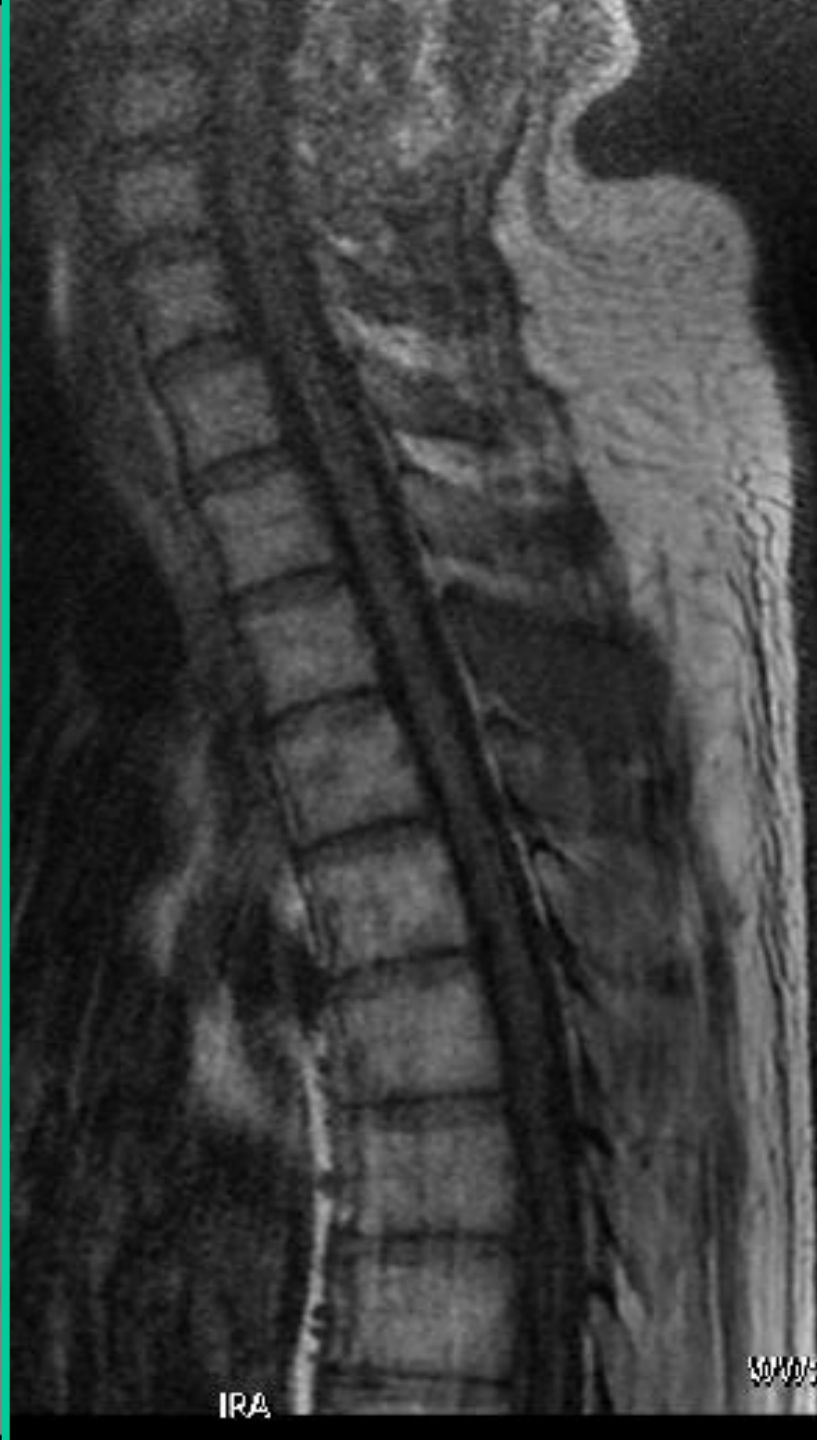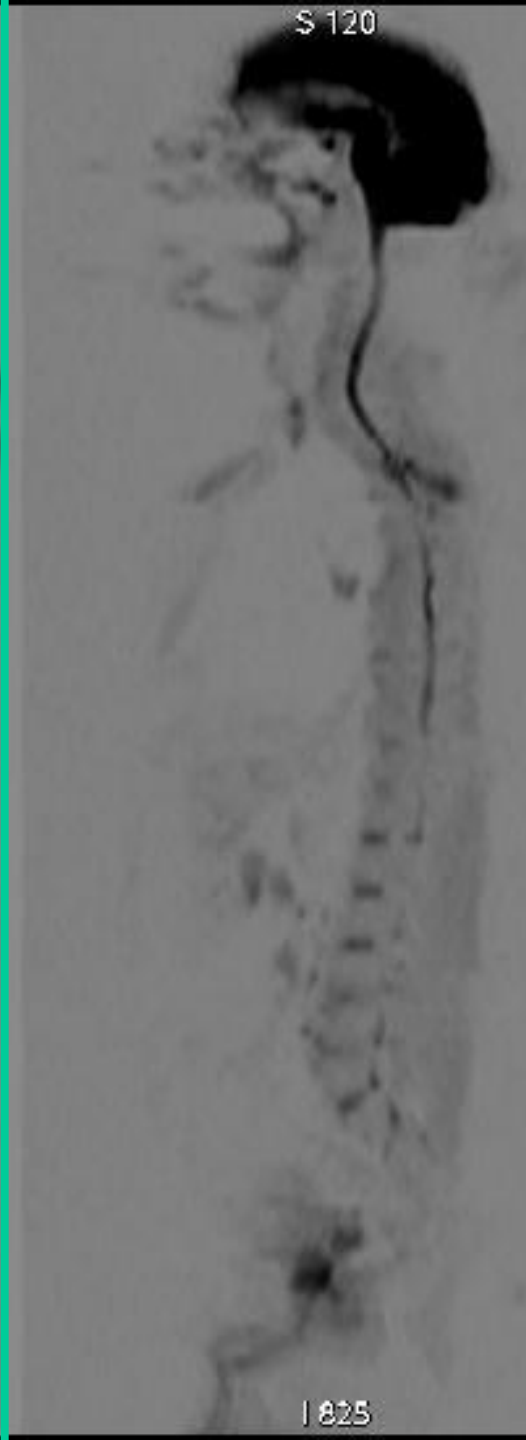
## Examen pré-thérapeutique



S 120



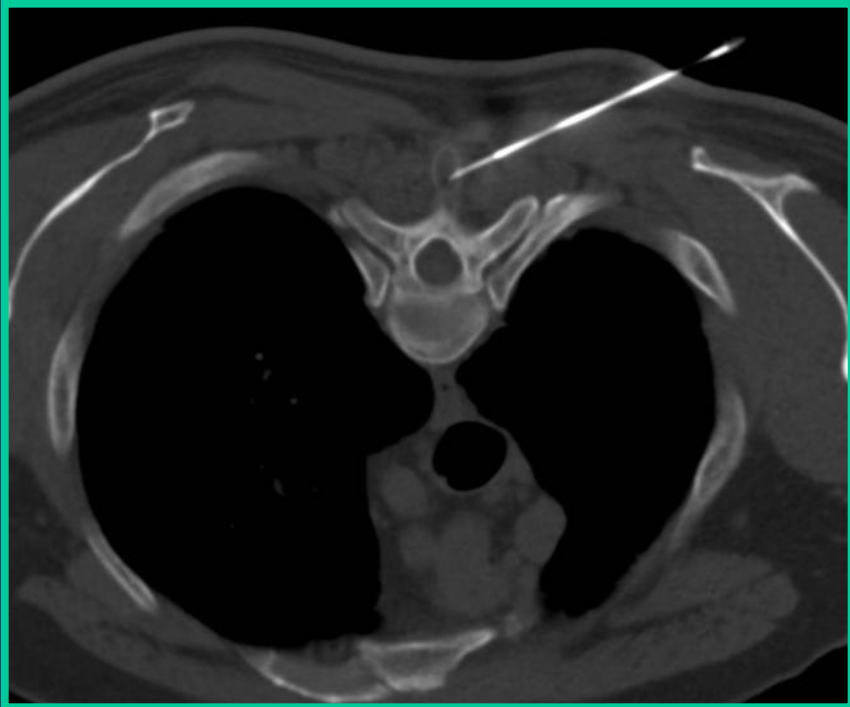
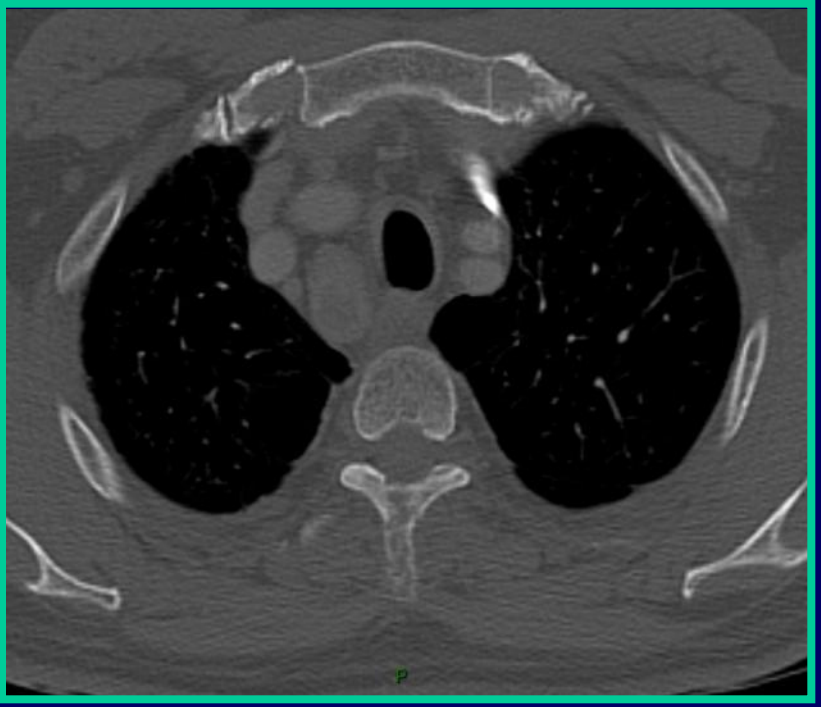
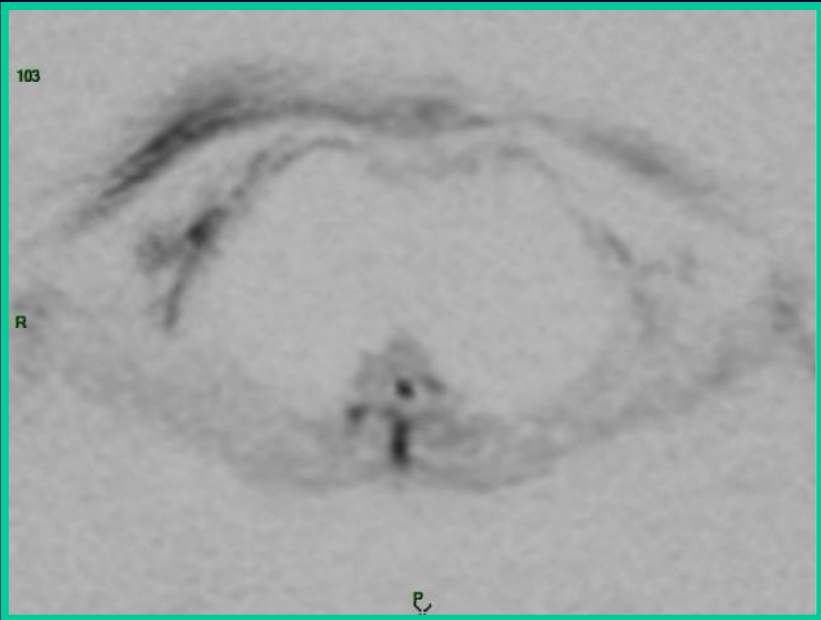
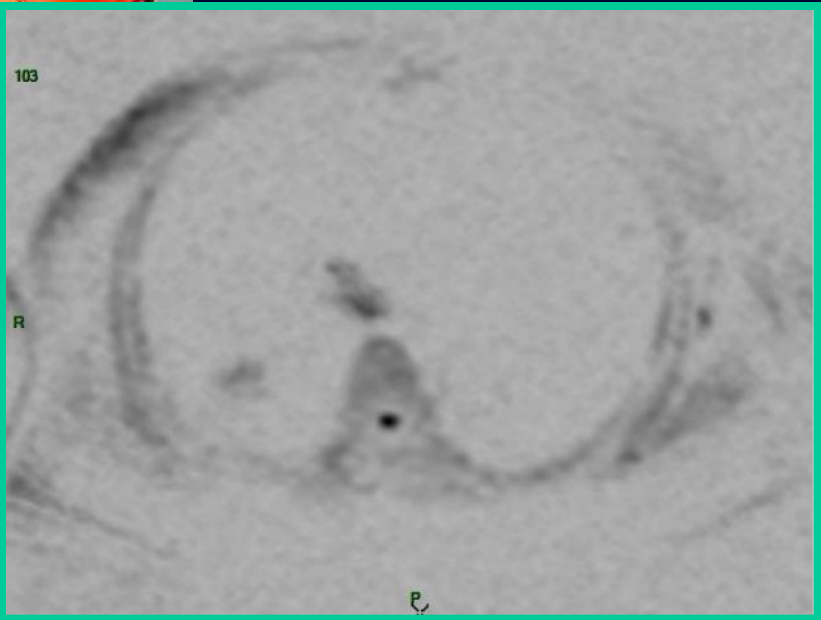
S 120





**Diagnostic?**

**Conduite à tenir**



Adénocarcinome bronchique



# **Nouvelle classification TNM T2N2M1**



# TEP

